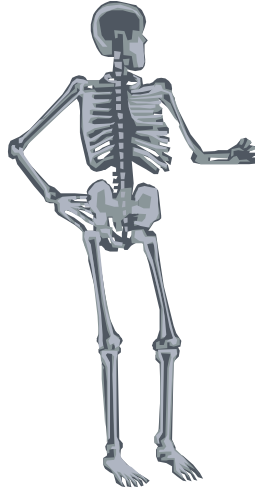

Bio& 241 A&P 1

Unit 2 / Lecture 3



Functional classification of joints

(based on degree of movement permitted within the joint)

- **Synarthrosis: Immovable joints**
 - a) *Sutures = joint between bones in the skull.*
 - b) *Synchondrosis = epiphyseal plate.*
 - *(Hyaline cartilage is eventually replaced by bone).*
 - c) *Synostosis = epiphyseal line of mature bones.*
- **Amphiarthrosis: Slightly movable joints**
 - a) *Syndesmosis = dense fibrous connective tissue located on the distal or proximal portion of long bones.*
(eg. distal tibia and fibula, also distal radius and ulna)
 - b) *Symphysis = cartilaginous joint (fibrocartilage).*
(eg. pubic symphysis and intervertebral discs)

Functional classification of joints

(based on degree of movement permitted within the joint)

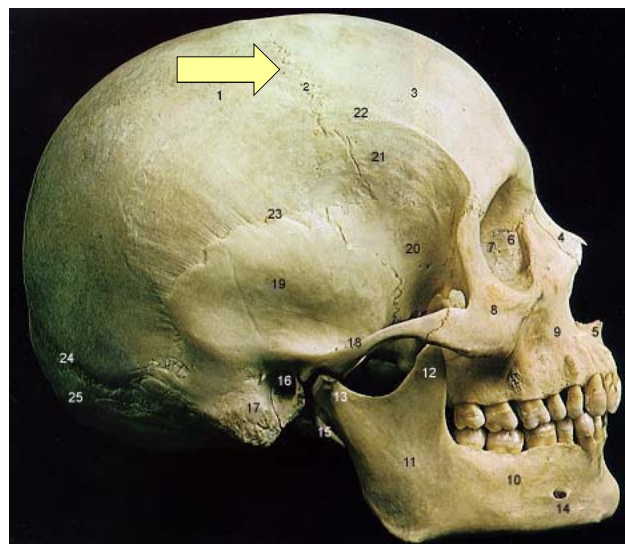
- **Diarthrosis: Freely movable joints**

c) synovial joints:

have a space between the bones called a synovial joint cavity, containing synovial fluid. The joint also has articular cartilage.

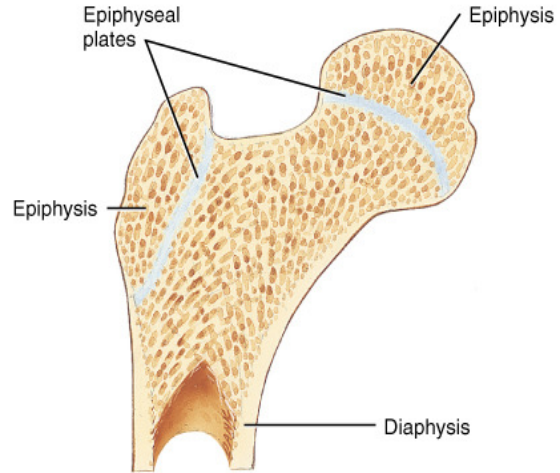
Synarthrosis: immovable joints

Suture



Synarthrosis: immovable joints

Synchondrosis

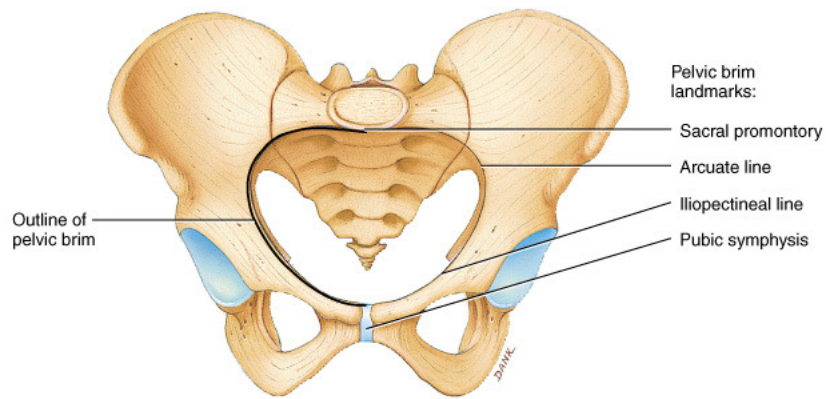


(a) Synchondrosis

© John Wiley & Sons, Inc.

Amphiarthrosis: Slightly movable joints

Symphysis

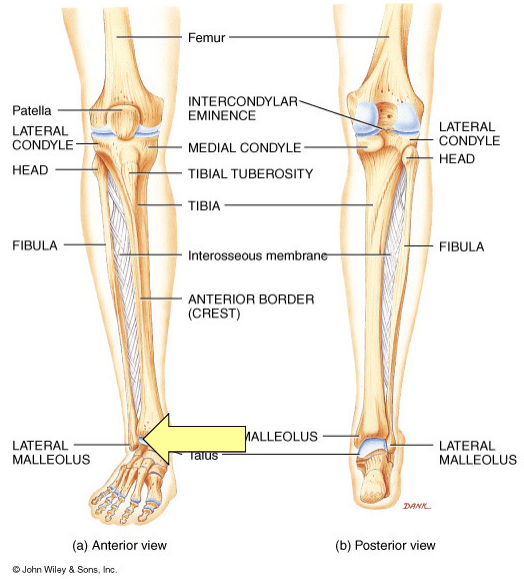


(a) Anterior view of borders of pelvic brim

© John Wiley & Sons, Inc.

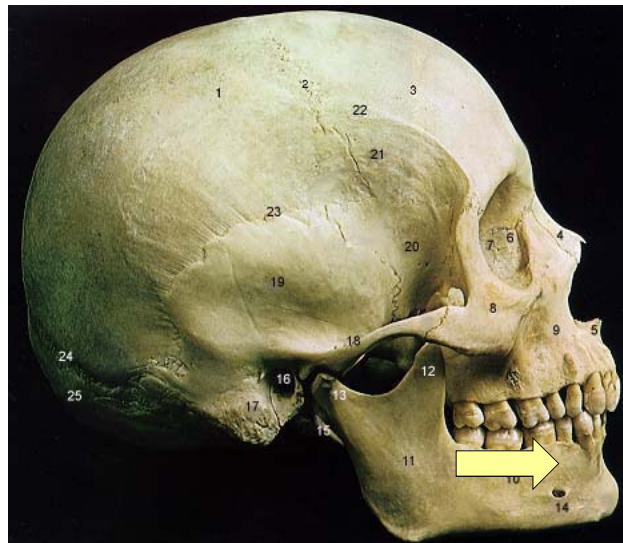Amphiarthrosis: Slightly movable joints

Syndesmosis

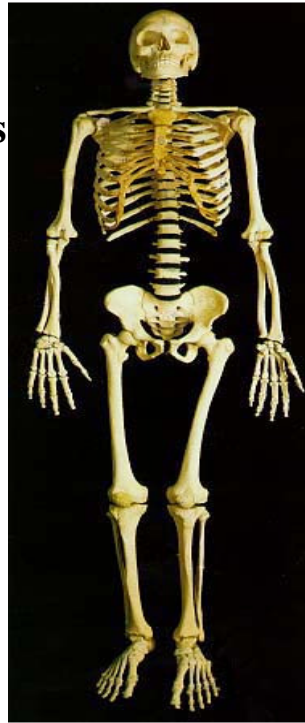

Synarthrosis or Amphiarthrosis?

Gomphosis



Diarthrosis:
freely movable joints



Structural classification of joints

(based on the presence or lack of a joint cavity and fibrous connective tissue)

•Fibrous Joints

NO joint cavity. Fibrous CT hold bones together.

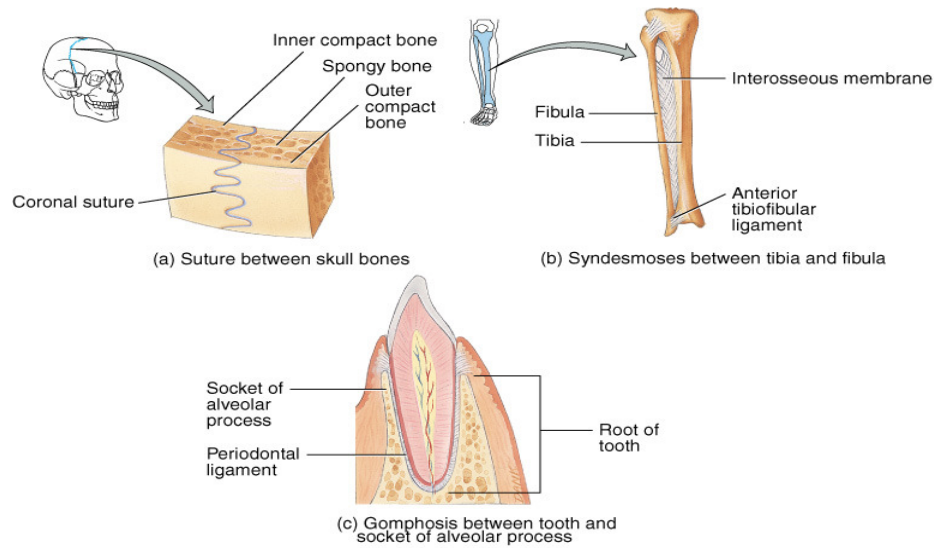
•Cartilaginous Joints

NO joint cavity. Cartilage connects bones together

•Synovial Joints

HAVE a joint cavity, containing synovial fluid, and ligaments which provide extra support. Cartilage is also present.

Fibrous joints

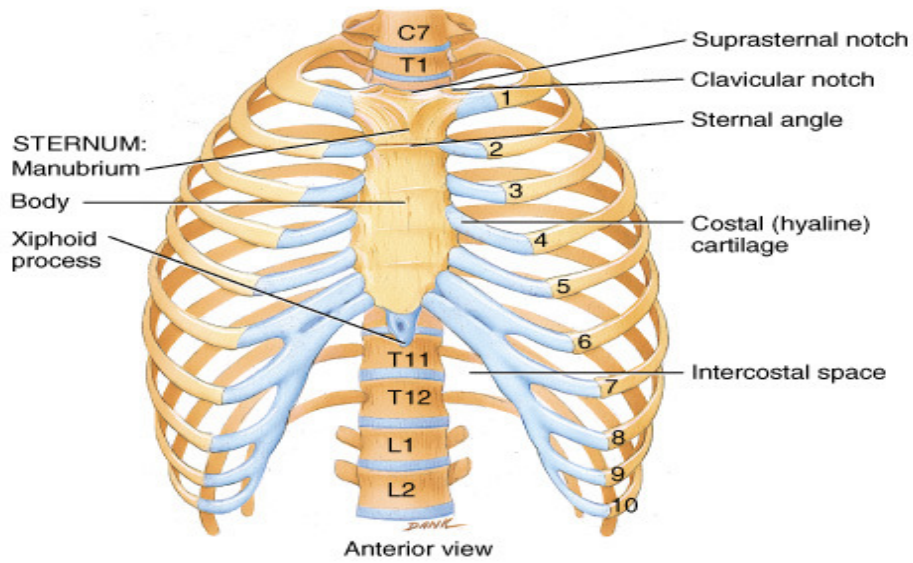


© John Wiley & Sons, Inc.

Cartilaginous Joints

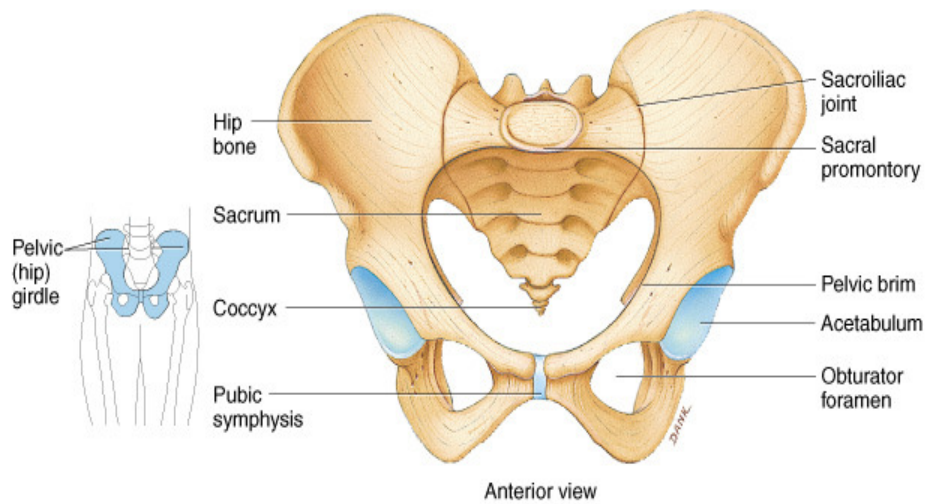
- Synchondroses: Epiphyseal plate
First Rib and Manubrium
- Symphyses: Pubic symphysis

Symphondrosis



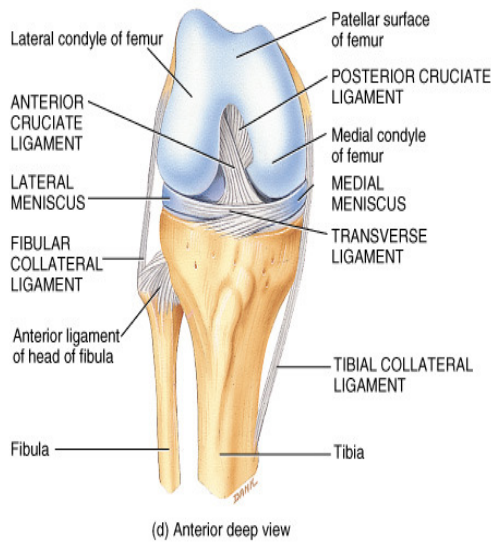
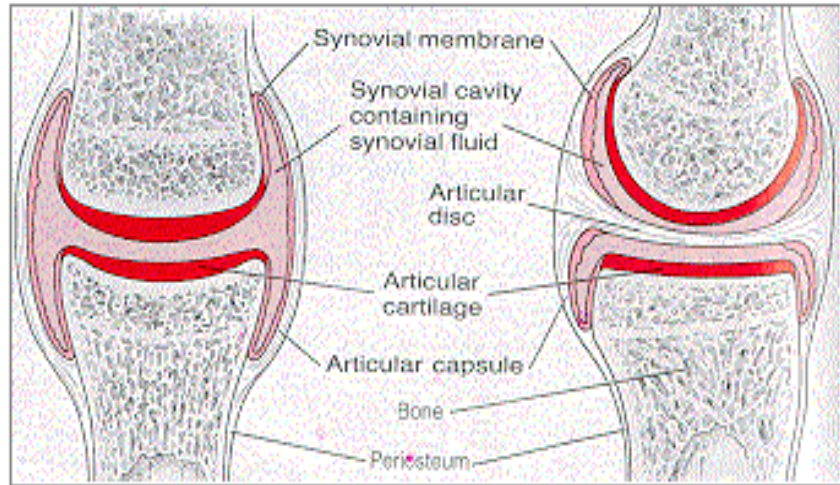
© John Wiley & Sons, Inc.

Symphysis

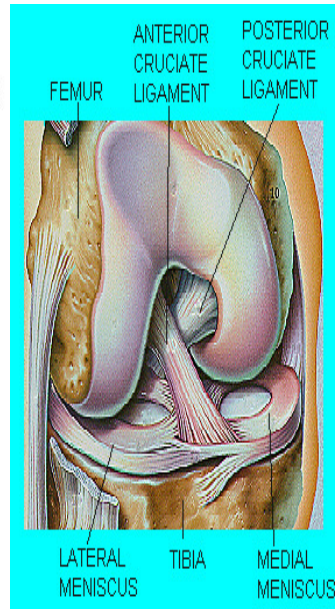


© John Wiley & Sons, Inc.

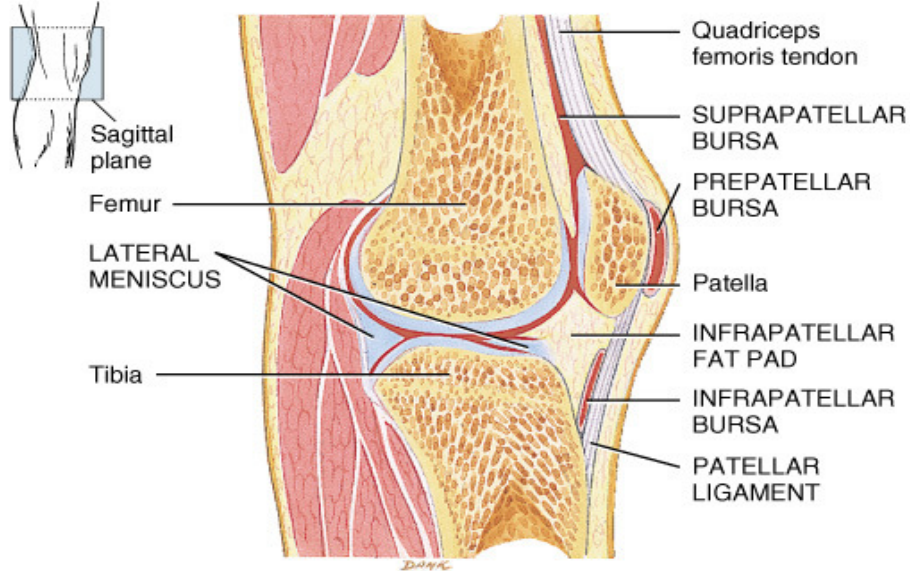
Synovial Joints



© John Wiley & Sons, Inc.

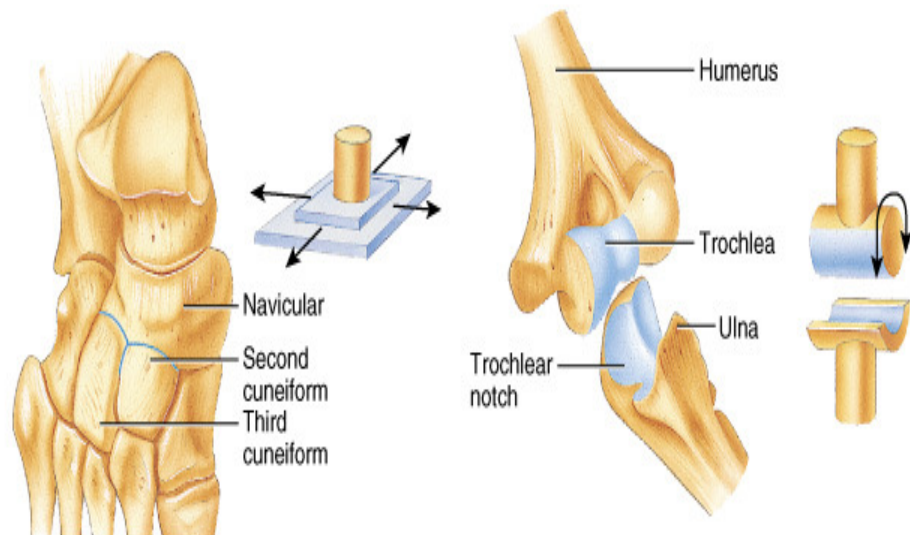


70% of knee injuries involve stretching or tearing the ACL



(c) Sagittal section

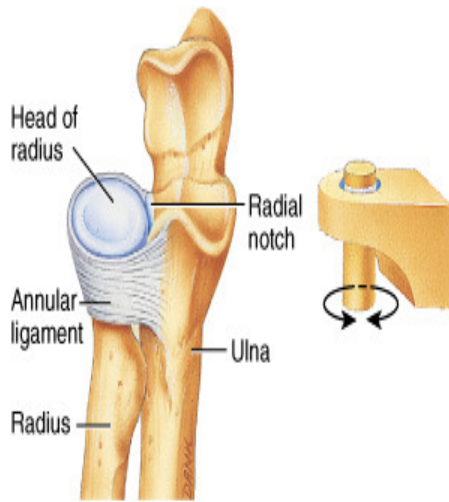
© John Wiley & Sons, Inc.



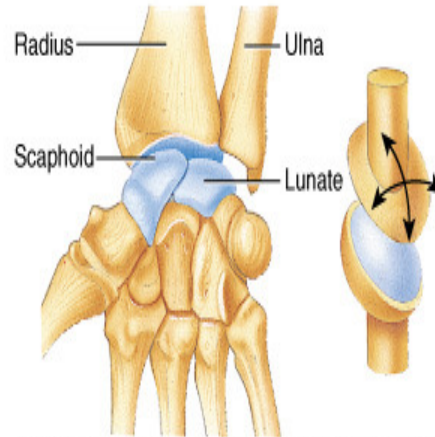
(a) Planar joint between the navicular and second and third cuneiforms of the tarsus in the foot

(b) Hinge joint between trochlea of humerus and trochlear notch of ulna at the elbow

© John Wiley & Sons, Inc.

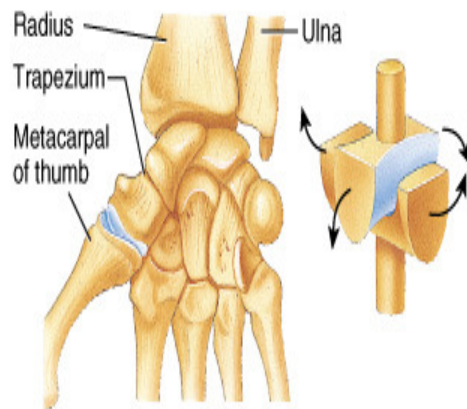


(c) Pivot joint between head of radius and radial notch of ulna

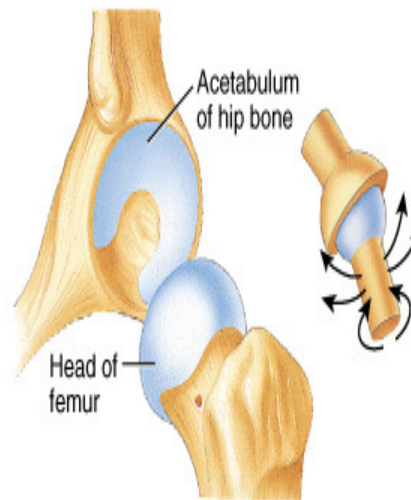


(d) Condyloid joint between radius and scaphoid and lunate bones of the carpus (wrist)

© John Wiley & Sons, Inc.

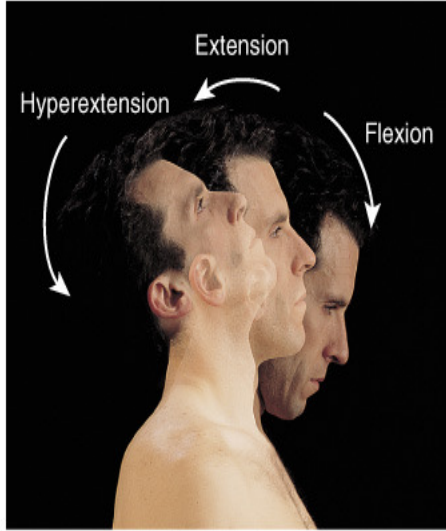


(e) Saddle joint between trapezium of carpus (wrist) and metacarpal of thumb



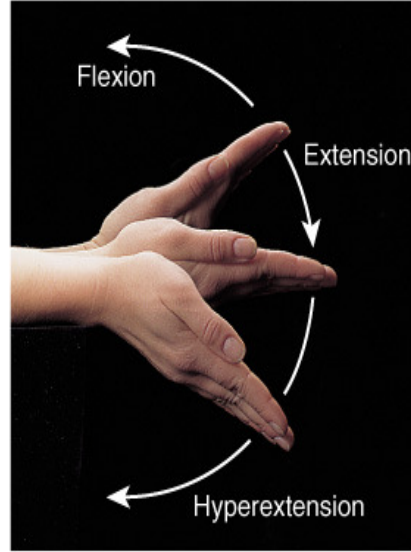
(f) Ball-and-socket joint between head of the femur and acetabulum of the hip bone

© John Wiley & Sons, Inc.



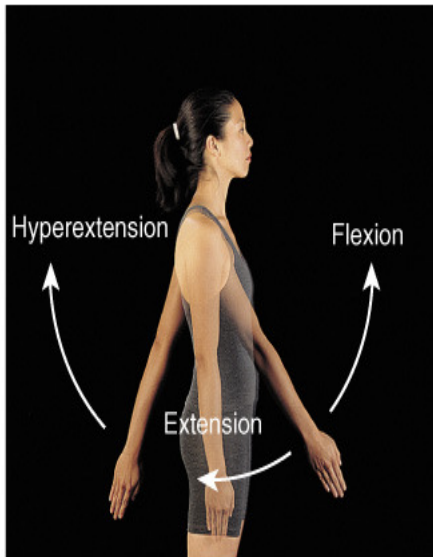
(a) Atlanto-occipital and cervical intervertebral joints

© John Wiley & Sons, Inc.



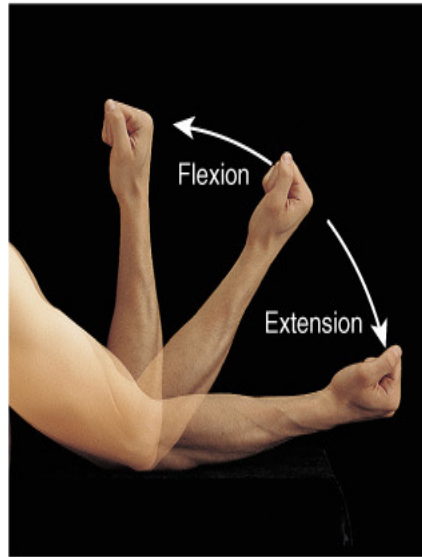
(d) Wrist joint

© John Wiley & Sons, Inc.



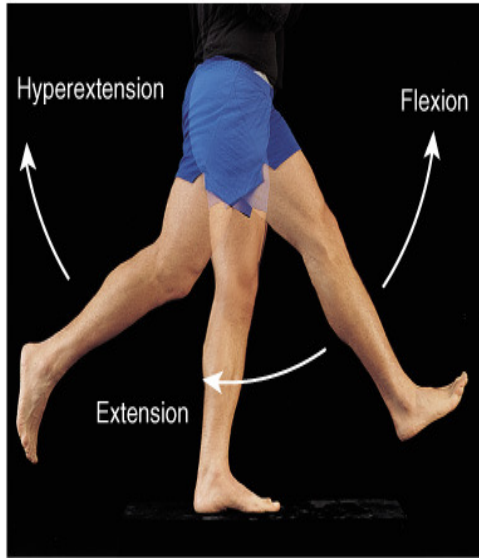(b) Shoulder joint

© John Wiley & Sons, Inc.



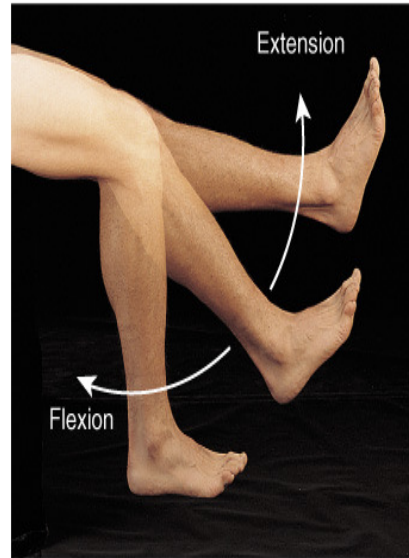(c) Elbow joint

© John Wiley & Sons, Inc.



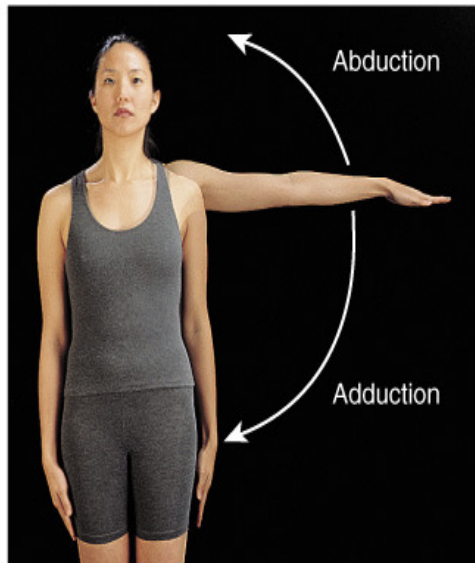(e) Hip joint

© John Wiley & Sons, Inc.



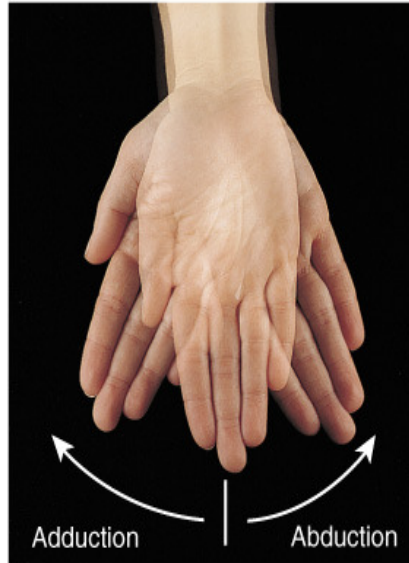
(f) Knee joint

© John Wiley & Sons, Inc.



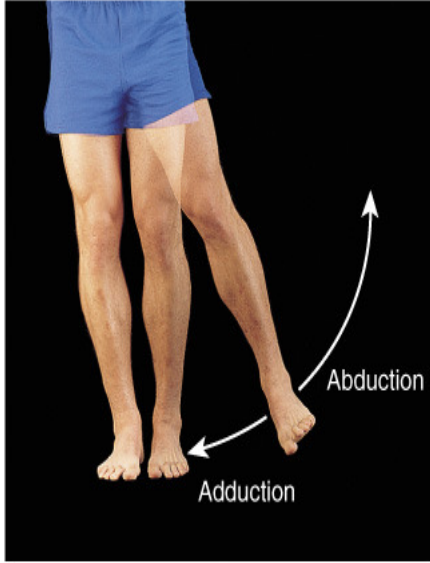(a) Shoulder joint

© John Wiley & Sons, Inc.



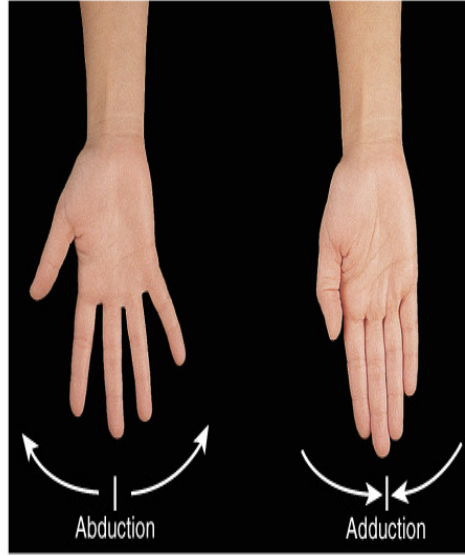
(b) Wrist joint

© John Wiley & Sons, Inc.



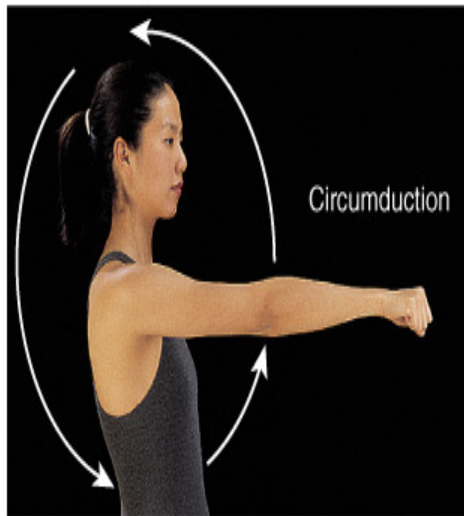(c) Hip joint

© John Wiley & Sons, Inc.



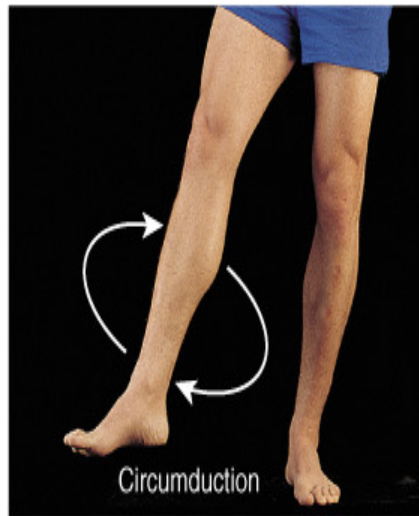(d) Metacarpophalangeal joints of the fingers (not the thumb)

© John Wiley & Sons, Inc.




(a) Shoulder joint

© John Wiley & Sons, Inc.

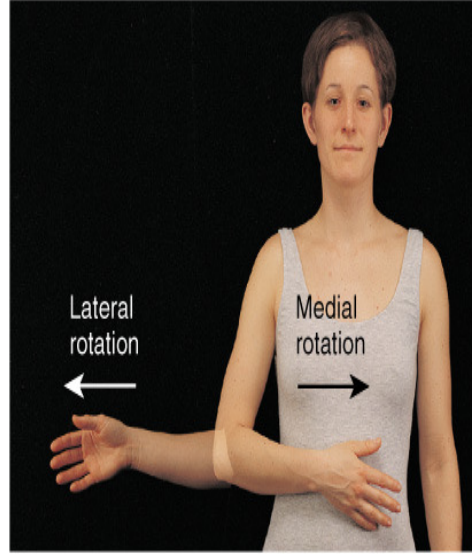


(b) Hip joint



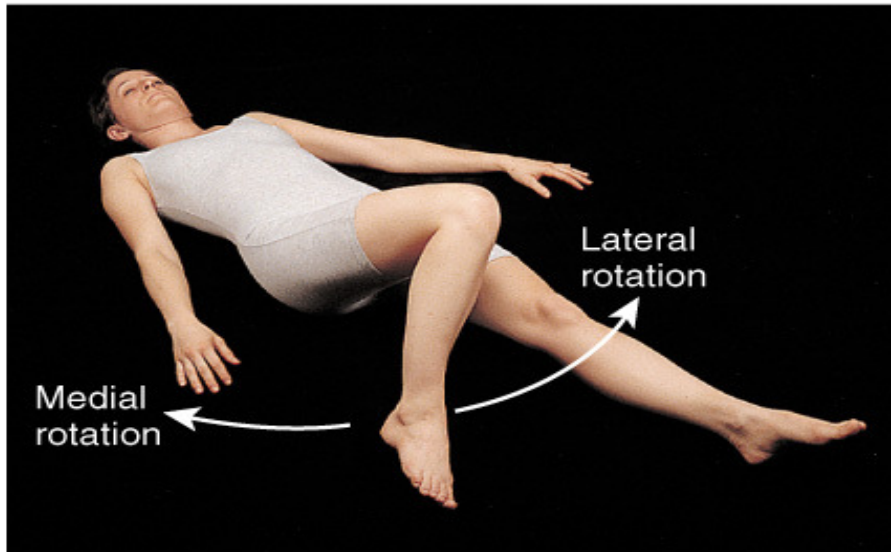
(a) Atlanto-axial joint

© John Wiley & Sons, Inc.



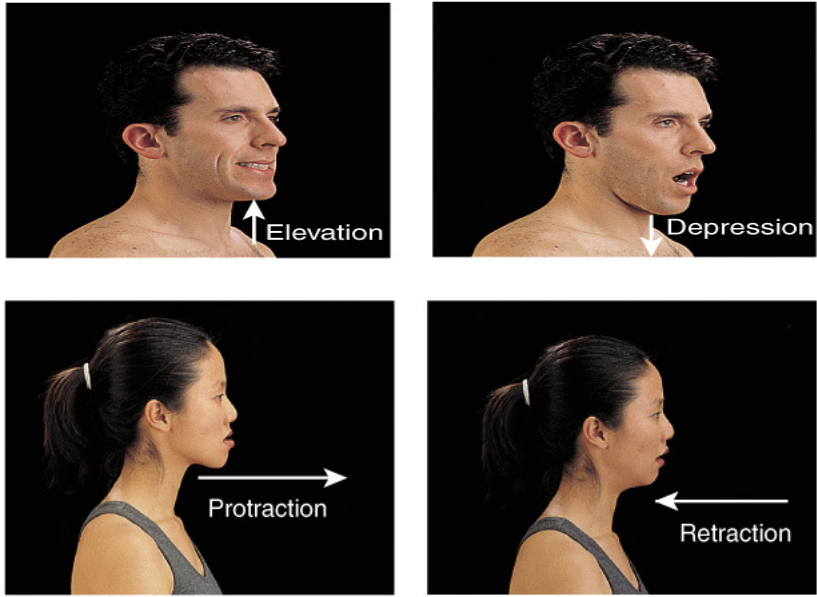
(b) Shoulder joint

© John Wiley & Sons, Inc.



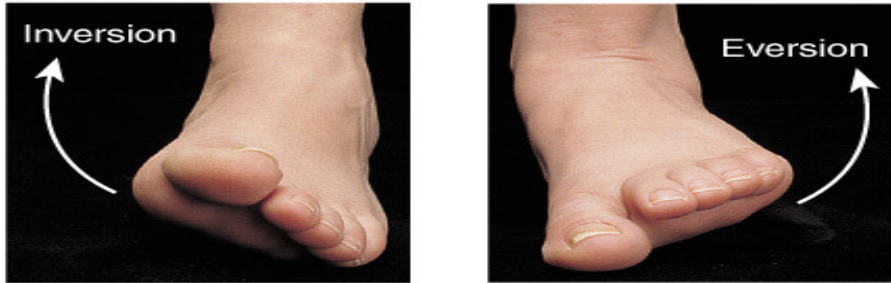(c) Hip joint

© John Wiley & Sons, Inc.

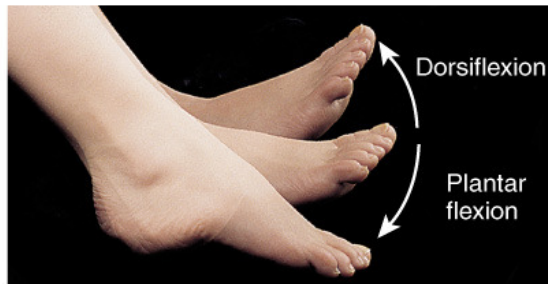

(c) Temporomandibular joint (d)

© John Wiley & Sons, Inc.

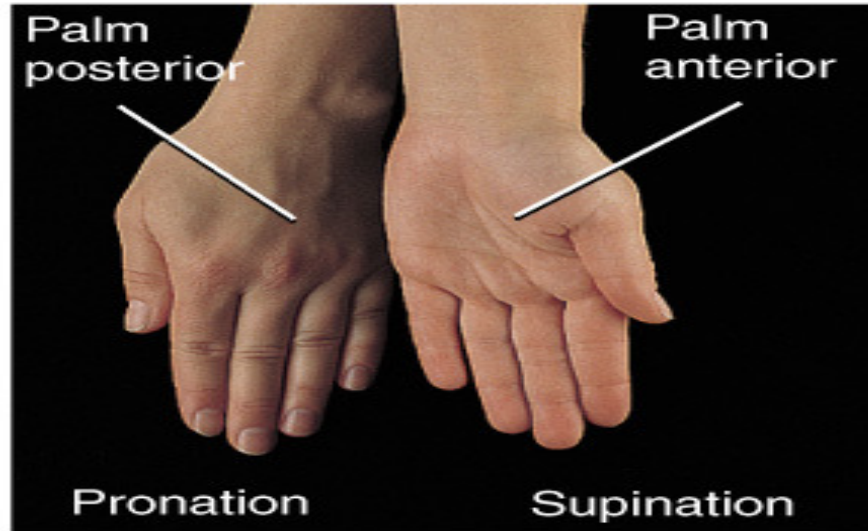


© John Wiley & Sons, Inc.



(g) Ankle joint

© John Wiley & Sons, Inc.



(h) Radioulnar joint

© John Wiley & Sons, Inc.